

# 'Street ketamine'—associated bladder dysfunction: a report of 10 cases

Peggy SK Chu 朱秀群  
SC Kwok 郭善淳  
KM Lam 林建文  
TY Chu 朱天儒  
Steve WH Chan 陳偉希  
CW Man 文志衛  
WK Ma 馬偉傑  
KL Chui 崔家倫  
MK Yiu 姚銘廣  
YC Chan 陳耀祥  
ML Tse 謝萬里  
FL Lau 劉飛龍

Ten young ketamine abusers presented with lower urinary tract symptoms to two regional hospitals in Hong Kong. Investigations demonstrated contracted bladders and other urinary tract abnormalities. These types of findings have never been reported before in ketamine abusers. The possible aetiology is also discussed.

## Introduction

Ketamine, an *N*-Methyl-D-aspartate receptor antagonist, is an anaesthetic agent characterised by a rapid onset and short duration of action. It has been used for the induction and maintenance of anaesthesia for more than 30 years<sup>1</sup> but has increasingly been abused as a 'club-drug' at dance and rave parties since the late 1980s.<sup>2</sup> This is an increasing problem in Hong Kong<sup>3</sup> and ketamine is now second only to heroin among psychotropic substances being abused.<sup>4</sup> Ten ketamine abusers (seven from Tuen Mun Hospital and three from Princess Margaret Hospital) were found to have severe bladder dysfunction—with markedly diminished functional bladder capacities of around 30 to 50 mL.

## Case reports

From 2000 to 2007, seven male and three female patients, aged 21 to 30 years (mean, 25 years) who had all abused ketamine for 1 to 4 years (Table), came to the two hospitals with severe lower urinary tract symptoms. All presented with symptoms of dysuria, frequency (having to void once every 15 minutes), urgency, urge incontinence, and painful haematuria. None had positive urine cultures. Early morning urines were all negative for acid-fast bacilli. The urine and blood toxicology profiles of some of these patients were positive for ketamine and benzodiazepam.

The functional bladder capacities obtained from the voiding diaries of all of the 10 patients were between 30 to 100 mL only. Urodynamic studies were available for seven patients up to the time of this review. Three patients failed to attend the urodynamic test despite explanation of the need for it. All seven patients were found to have detrusor overactivity with urinary leakage when the bladder was filled to a capacity of 30 to 50 mL

### Key words

Ketamine; N-methylketamine; Urinary bladder, neurogenic

*Hong Kong Med J* 2007;13:Epub 2007 Jun 21

Department of Surgery, Tuen Mun Hospital, Hong Kong  
PSK Chu, FRCS (Edin), FHKAM (Surgery)  
SC Kwok, MB, BS, MRCS  
KM Lam, FRCS (Urology), FHKAM (Surgery)  
TY Chu, MB, ChB, MRCS  
SWH Chan, FRCS (Urology) (Edin), FHKAM (Surgery)  
CW Man, FRCS (Edin, Glasg), FHKAM (Surgery)  
Princess Margaret Hospital, Laichikok, Hong Kong:  
Department of Surgery  
WK Ma, MB, ChB, MRCS  
KL Chui, MB, BS, MRCS  
MK Yiu, FRCS (Edin), FHKAM (Surgery)  
Hong Kong Poison Information Centre  
YC Chan, FRCS (Edin), FHKAM (Emergency Medicine)  
FL Lau, FRCS (Edin), FHKAM (Emergency Medicine)  
Department of Accident and Emergency, United Christian Hospital, Hong Kong  
ML Tse, FRCS (Edin), FHKAM (Emergency Medicine)

TABLE. Physical characteristics, clinical and radiological features of the 10 patients

Patient No.	Sex/Age (years)	Date of presentation	Duration of taking ketamine (years)	ALP/ALT* (U/L)	Serum creatinine (µmol/L)	USG† kidney
1	F/25	Nov 2000	1	382/129	400	B hydro
2	M/30	Jun 2006	2	142/27	220	B hydro
3	M/30	Sep 2006	4	413/83	177	B hydro
4‡	M/25	Jan 2007	Unknown	558/407	99	B hydro
5‡	F/22	Jan 2007	Unknown	164/74	46	B hydro
6	M/25	Feb 2007	2	114/114	85	Normal
7	M/26	Mar 2007	Unknown	124/242	95	B hydro
8§	M/20	Mar 2007	Unknown	107/40	75	Normal
9§	M/21	Mar 2007	1	624/1141	237	B hydro
10	F/26	Apr 2007	1	229/48	100	B hydro

\* ALP denotes alkaline phosphatase (reference range, 46-127 U/L); and ALT alanine aminotransferase (reference range, 10-57 U/L)

† USG denotes ultrasonography, and B hydro bilateral hydronephrosis

‡ Patients 4 and 5 are a couple; patient 5 became a ketamine abuser after marrying patient 4

§ Patient 8 was prescribed cimetidine while patient 9 was prescribed omeprazole for epigastric pain

Correspondence to: Dr PSK Chu  
E-mail: peggychului@gmail.com

(Figs 1 and 2), and this was associated with bilateral reflux in one case and unilateral reflux in two cases. Seven patients had ultrasonographic evidence of bilateral hydronephrosis at the time of diagnosis (Fig 3). Four of the patients had cystoscopies and random biopsies performed showed cystitis glandularis only.<sup>5</sup>

Three patients had magnetic resonance imaging of the lumbosacral spine, all of which were normal. All 10 patients had abnormal liver function tests with raised levels of alkaline phosphatase and alanine aminotransferase. Ultrasound examinations did not demonstrate any underlying obstructive cause in any of these patients, and none were found to have hepatitis B–associated chronic liver disease. Ketamine clearance is mainly hepatic and flow dependant,<sup>6,7</sup> and it has been reported that the CYP3A4 is the principal microsomal enzyme involved in ketamine metabolism.<sup>8,9</sup> Seven of these patients had complained of epigastric pain and had oesophagogastroduodenoscopies (OGD) performed. Although none had positive OGD findings some were given cimetidine or omeprazole, which are known to be CYP3A4 inhibitors, for a short period and this may have contributed to the abnormal liver function in these patients.

Patient 2 was given an augmentation enterocystoplasty with the aim of maintaining renal function and improving his quality of life. Despite our advice, he continued to abuse ketamine after the augmentation enterocystoplasty, and was admitted 3 months later in acute renal failure with a serum creatinine of 554  $\mu\text{mol/L}$  and oliguria. An urgent ultrasound of the kidneys revealed gross bilateral hydronephrosis so bilateral percutaneous nephrostomy drainage was performed. The patient's serum creatinine then improved slowly, falling to 170  $\mu\text{mol/L}$ . A subsequent antegrade nephrostogram revealed complete right-sided ureteric obstruction just below the pelvic-ureteric junction (PUJ) and a markedly diminished flow of contrast in the left ureter suggestive of retroperitoneal fibrosis (Figs 4 and 5).

## Discussion

An association between 'street ketamine' abuse, bladder dysfunction and subsequent renal impairment has not been previously reported. No animal studies into the effects of ketamine have revealed these types of disorders, nor has the pharmaceutical company marketing ketamine ever encountered such pathology after long-term exposure in both animals and humans. All 10 patients demonstrated an association between ketamine abuse and lower urinary tract pathology. This specific disease caused intractable urinary symptoms and severe impairment of their quality of life. Most importantly, the finding

## 與「街頭」氯胺酮有關的膀胱功能失調： 十宗病例報告

十名氯胺酮濫用者因呈有下尿道徵狀分別被送往兩間香港地區醫院，經檢查後發現膀胱收縮及其他尿道異常。這是於氯胺酮濫用者身上發現這類結果的首批病例報告。本文亦討論導致以上情況的可能病原。

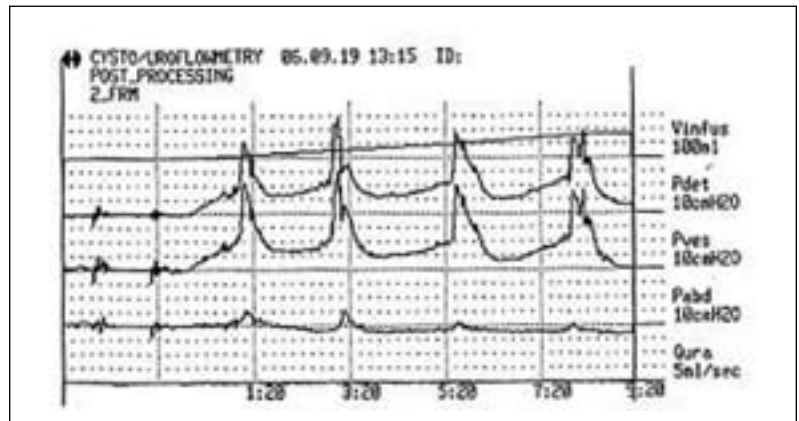


FIG 1. Urodynamic tracing of patient 2 demonstrating phasic unstable contraction when bladder filled to around 30 mL only, associated with urinary leakage

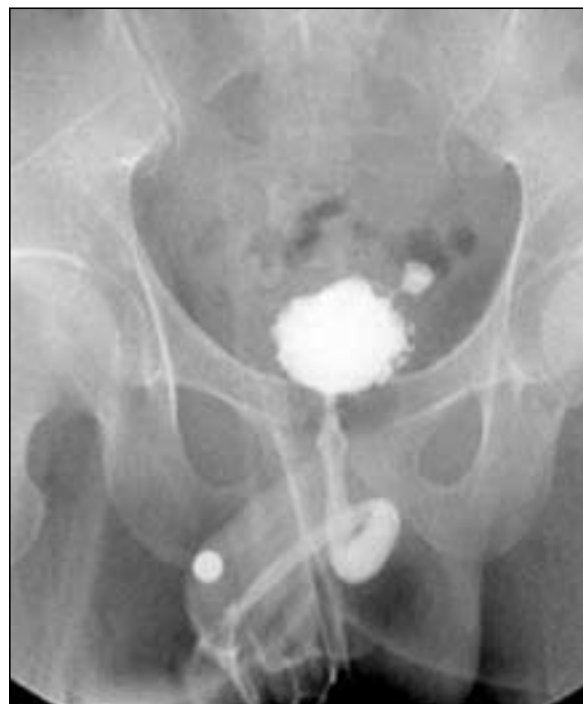

FIG 2. Video-urodynamic study of patient 2 with markedly contracted and trabeculated bladder

of hydronephrosis in most, and renal impairment in half, of our patients is suggestive of a progressive disease process that might end up as chronic renal failure. The aetiology of this disease is presently

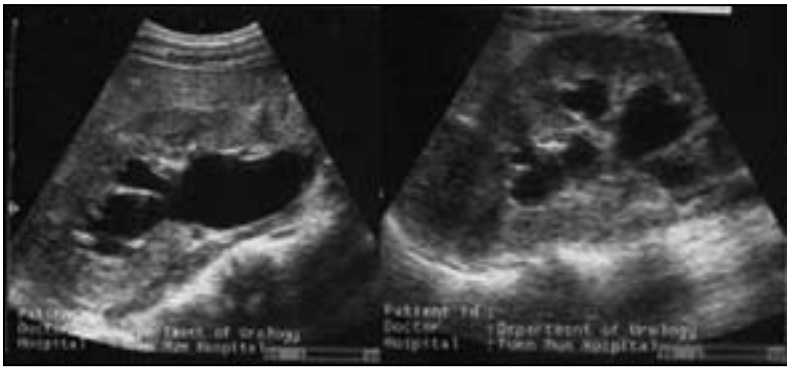

FIG 3. Ultrasound kidneys of patient 5 showing bilateral hydronephrosis

unknown. We initially postulated that damage to neurons in the brain or the spinal cord was the cause of the bladder dysfunction. Nonetheless, patient 2's pathology—bilateral ureteric strictures, suggestive of retroperitoneal fibrosis—implies that another aetiology like an intensive immunological response to 'street ketamine' may be a contributing factor. Possible causes include the direct toxic effect of ketamine and its metabolites on the lower urinary tract mucosa. Ketamine abusers are likely to be exposed to other drugs and chemicals either purposefully added as a cutting agent or being co-abused in a soft drug cocktail.<sup>10</sup> One sample of snorting ketamine powder was obtained from one of our patients and analysed but this failed to identify any additional ingredient likely to cause the bladder dysfunction. Further investigation is needed to determine the exact cause of the pathology. An epidemiological study would be helpful for assessing the actual size of the problem and may yield clues to the aetiology as well. The authors would like to alert frontline doctors, especially those working in primary care, emergency departments, and psychiatry, to this new form of uropathy and its association with ketamine abuse. Early urology referral for comprehensive investigation and management would help combat this new form of urinary tract disease.

## References

- White PF, Way WL, Trevor AJ. Ketamine—its pharmacology and therapeutic uses. *Anesthesiology* 1982;56:119-36.
- Tellier PP. Club drugs: is it all ecstasy? *Pediatr Ann* 2002;31:550-6.
- Joe Laidler KA. The rise of club drugs in a heroin society: the case of Hong Kong. *Subst Use Misuse* 2005;40:1257-78.
- Hong Kong Narcotics Report 2006. Narcotics Division, Security Bureau, HKSAR Government.
- Shahani R, Streutker C, Dickson B, Stewart RJ. Ketamine-associated ulcerative cystitis: a new clinical entity. *Urology* 2007;69:810-2.
- Clements JA, Nimmo WS, Grant IS. Bioavailability, pharmacokinetics, and analgesic activity of ketamine in humans. *J Pharm Sci* 1982;71:539-42.
- Malinovsky JM, Servin F, Cozian A, Lepage JY, Pinaud M. Ketamine and norketamine plasma concentrations after i.v., nasal and rectal administration in children. *Br J Anaesth* 1996;77:203-7.
- Hijazi Y, Boulieu R. Contribution of CYP3A4, CYP2B6, and CYP2C9 isoforms to N-demethylation of ketamine in human liver microsomes. *Drug Metab Dispos* 2002;30:853-8.
- Ko JW, Sukhova N, Thacker D, Chen P, Flockhart DA. Evaluation of omeprazole and lansoprazole as inhibitors of cytochrome P450 isoforms. *Drug Metab Dispos* 1997;25:853-62.
- Lam CW, Boey KW, Wong OO, Tse SK. Report on a study of substance abuse in the context of underground rave culture. Hong Kong: Research Sub-committee of the Action Committee Against Narcotics; 2004.

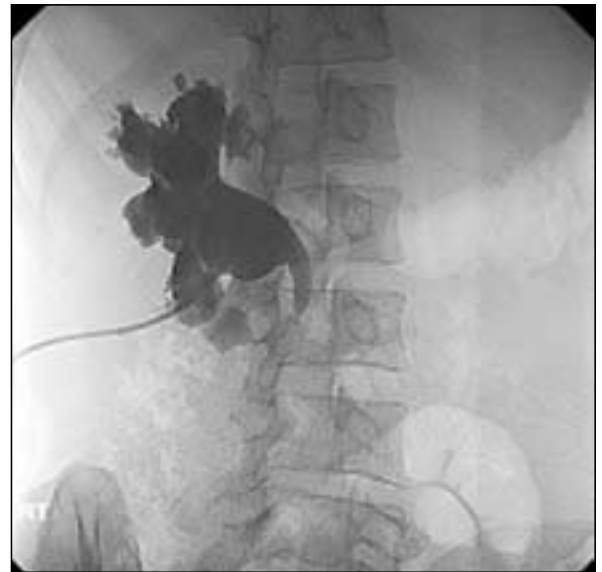

FIG 4. Right antegrade nephrostogram of patient 2 showing complete obstruction just below the pelvic-ureteric junction level

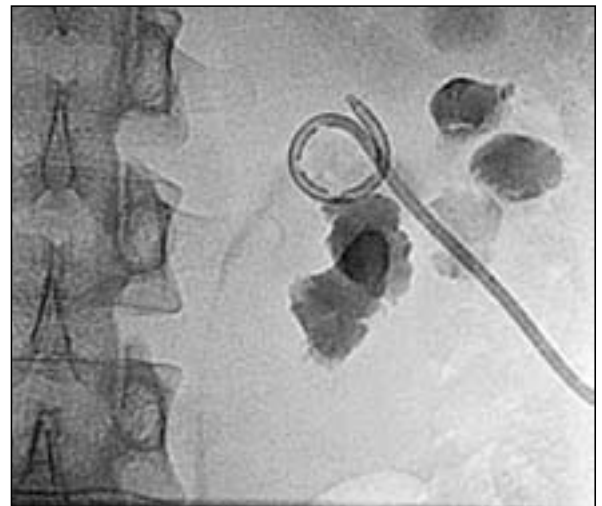

FIG 5. Left antegrade nephrostogram of patient 2 showing markedly diminished flow of contrast in the left ureter all the way to below the pelvic-ureteric junction